

Effects of longstanding inguinal hernia on the microstructure of testis and spermatic tract system

M. Tariq. Zaidi and Aijaz. A. Khan

Department of Anatomy JNMC AMU Aligarh

Abstract

Scrotal position of testes in man is believed to be a homeothermic specialization. Maldescent of testis is known to be associated with male infertility. Contents of longstanding hernia coming in close contact with the spermatic tract system are expected to disturb the thermo-regulatory process of testis and hence likely to affect the spermatogenesis. In the present study a 50-year-old male had a long-standing right inguinal hernia. He was operated and large defect necessitated ligation and excision of spermatic cord along with herniorrhaphy. Tissues thus obtained (Testis, Epididymis, Vas deferens and associated blood vessels) were fixed in 10% formalin and processed for paraffin sections. Observations were made on H & E and Weigert stained slides under light microscope. In the testis the tubular basement membrane appeared thickened, all stages of spermatogenic cells were scanty and tubular lumen was completely devoid of sperms. The interstitial cells of Leydig appeared hyperplastic and hypertrophied. Duct of epididymis was appeared normal with preservation of characteristic stereocilia. However, the part of the duct located relatively deep in the body of epididymis showed degenerative changes. The ductus deferens had normal microstructure. Testicular artery lumen was full of blood and its all tunics revealed features of both hyperplasia and hypertrophy to the extent that overall thickness of its tunics matched with that of the ductus deferens. Vein also revealed congestion. It was concluded that long standing inguinal hernia even in the absence of varicocele has harmful effect on the spermatogenesis and hence warrants early treatment.

Key Words: Inguinal hernia, Spermatogenesis, Leydig cells, Thermoregulation, Spermatic tract

Accepted January 06 2011

Introduction:

In humans, testis develops in the lumbar region but during prenatal life it descends down to assume its final position inside the scrotum. From the studies related to undescended testis its analogous experiments it has been concluded that scrotal position of testis is necessary for optimal spermatogenesis and fertility. Among many possible factors affecting spermatogenesis, a few degree lower temperature than core temperature of the body is considered to be most important external factor that can affect the normal spermatogenic process. Like many factors, which help to maintain the optimal testicular temperature, there are equally many clinical conditions such as varicocele, hydrocele, filariasis and complete inguinal hernia which interfere with thermoregulatory mechanisms and spermatogenesis. Keeping in mind the above possibility, present study was conducted to assess the harmful effects of long standing inguinal hernia on the spermatic tract and associated vessels.

Material and Method:

A fifty year old male complained of long standing inguinoscrotal swelling which was associated with off and on dragging pain. On clinical examination it was found to be a case of long standing complete inguinal hernia. On his request he was operated under spinal anesthesia. Gross examination of hernia revealed usual contents. There was no sign of varicocele. He had large defect in the inguinal canal therefore the surgical procedure involved herniorrhaphy along with ligation and excision of spermatic tract system. The tissue material thus obtained were immersion fixed in 10% formalin and processed for paraffin embedding. Light microscopic observations were made on H&E and Weigert's stained slides.

Observations

Gross. Per-operative findings showed a large hernial sac containing intestine and its mesentery along with its cove-

rings and contents of spermatic tract system of size 6 X 10 inches occupying whole inguinal region and extending

into the scrotum with no signs of varicocele

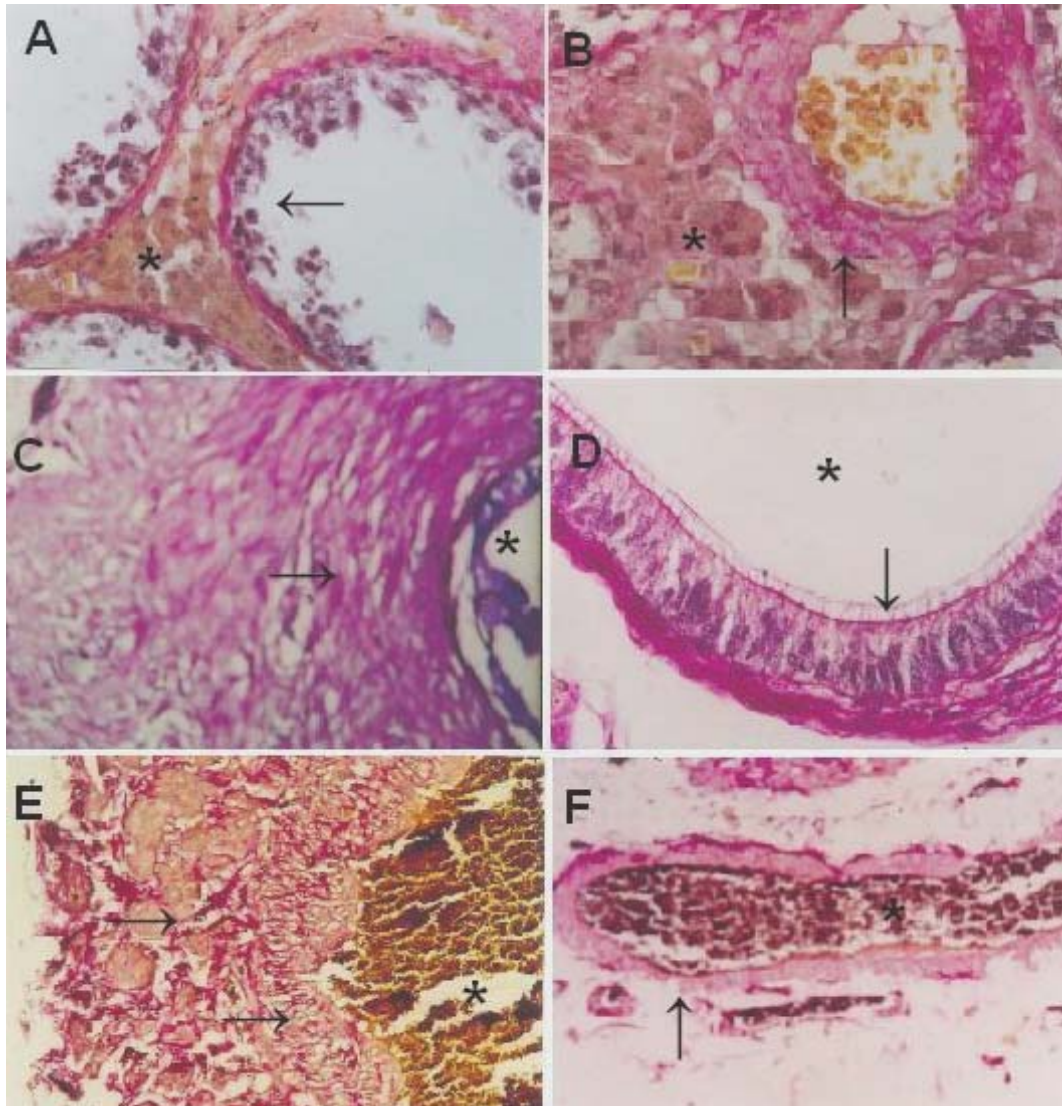


Figure 1. Sample photomicrographs from the spermatic tract and associated blood vessels. Cross section of three seminiferous tubules (A) showing prominent basement membrane, paucity of spermatogenic cells (arrow) and cluster of interstitial cells (*). Fig. (B) shows thickened tunica media (arrow) and congestion of a branch from testicular artery, and large cluster of interstitial cells with eccentric nuclei. Spermatic cord (C) shows usual features with its lumen (*) and thick muscle coat (arrow). Epididymis (D) also shows normal features with its lumen (*) and intact stereocilia (arrow). Testicular artery (E) shows highly thickened tunica media (arrows) and lumen filled with blood. Vein (F) shows normal features with thin wall (arrow), collapsed lumen (*) filled with blood. H &E and Weigert's stain.

Microscopic

The seminiferous tubules revealed thickened basement membrane, scarcity of all stages of spermatogenic cells, disorganization of seminiferous epithelium and complete absence of sperms inside the lumen. (Fig.1A). The interstitial cells looked normal and in fact at places they formed big clusters with their characteristic eccentric nuclei. (Fig.1B).The interstitial blood vessels revealed congestion and hyperplasia in their walls (Fig. 1B). The microstructure of epididymis appeared normal with preser-

vation of stereocilia on the luminal aspect of epithelial cells (Fig 1D). However, the part of its duct located relatively deep from the surface showed obvious degenerative changes in the form of sloughing of its epithelium. Lumen was completely devoid of sperms. Ductus deferens was apparently normal with its characteristic thick muscular wall and mucosal folds (Fig. 1C). Testicular artery revealed engorgement and its tunica media was hypertrophied to the extent that its thickness matched the wall of ductus deferens and its wall had large number of vasa-

vasora. Tunica intima also showed proliferative changes (Fig. 1E). However pampiniform plexus of veins did not show any specific change (Fig 1F).

Discussion:

Testis develops in the lumbar region and begins its descent for its final position during fetal life so that in the newborn it is commonly located inside the scrotum [1]. Thus, after birth it almost always remains outside the abdominal cavity where temperature remains few degrees lower than the core temperature. The thermoregulation within a narrow limit is maintained by many factors e.g., presence of insulating hair, dartos muscle altering the heat radiant area, muscular bag of cremaster and prompt cremasteric reflex and effective countercurrent heat exchange mechanism between blood of testicular vessels [2] Although spermatogenesis begins only at puberty, provision for a precise thermoregulation is very much in place just after birth, probably to ensure optimal thermal condition for resting spermatogonia, which are susceptible to core body temperature similar to their active counterparts during puberty. This appears plausible from the observations that individuals having undescended testis could not gain normal fertility even if got it relocated during childhood [1]. In the present study, the patient was fertile and completed his family before the development of hernia. However, after long-standing hernia his testis showed changes (loss of spermatogenic cells, absence of sperms in the tubular lumen, and thickened tubular basement membrane) suggestive of significant damage affecting spermatogenesis and fertility. The patient had neither himself undergone fertility checkup before nor after the surgical procedure.

When the thermoregulatory mechanism is compromised due to any factor such as ectopic testis, vascular congestion due to hyper-vascularization and stasis due to poor venous return, or prolonged apposition of hernial contents to the testis, it is exposed to a relatively hyperthermic condition. In such circumstances many of the temperature dependent enzymes responsible for DNA synthesis in the testis may not work [3,4]. Altered microstructure in terms of thickened tunica media of artery and clogged lumen of both testicular artery and pampiniform plexus of veins suggestive of such mechanism which might have worked in this case. In addition, increased blood flow to testis can affect the spermatogenesis [5,6]. Failure of cremasteric reflex because of failure of the cremaster muscle to support large hernial sac within the cremaster muscle would have also affected thermoregulation. High division and ligation of pampiniform plexus in case of varicocele may provide psychological relief but does not relieve testis from hypervascular state. An increase in hydrostatic pressure with a change in filtration pressure alters the composition of the interstitial fluid [7] this alteration could change the intimate paracrine communications be-

tween the Leydig cells, peritubular myoid cells and Sertoli cells, thus ultimately affecting the spermatogenesis [8]

A thickened basement membrane of seminiferous tubule and proliferative lesion of endoepithelium are often demonstrated which may affect transportation of oxygen and glucose, a change very akin to those seen in varicocele [9,10]. Both Sertoli cells and Leydig cells are said to regulate spermatogenesis by steroidogenesis and growth factors production. [11,12]. Sertoli cell stimulated by FSH produce inhibin and activin [13]. Inhibin has negative feedback control on pituitary and FSH secretion. Inhibin also binds to Leydig cells regulating testosterone production. Activin binds to round spermatids and spermatogonia and thus affecting spermatogenesis. Varicocele affects the adluminal compartment, and Sertoli cells are more sensitive to perturbation of the testicular environment than germ cells. Thus Sertoli cell may be the primary intratubular site of alteration leading to spermatogenic disruption. Leydig cells are under control of luteinizing hormone (LH) and responsible for testosterone production. However, it is believed that it is the intratesticular testosterone that is more important in regulation of spermatogenesis [14,15]. High level of LH seen in varicocele is associated with Leydig cell hyperplasia [16,17,18]. Thus, Leydig cell hyperplasia as noticed in the present case of inguinal hernia suggests some commonality with varicocele in the causation of infertility. It is concluded that long standing inguinal hernia may lead to disturbance of testicular thermoregulation and vascular changes sufficient enough to produce hypogonadism and infertility and hence warrants early treatment with preservation of cremaster muscle.

References

1. Sadler TW Langman's Medical Embryology: Testis 9th edition Lippincott Williams and Wilkins 351 West Camden Street Baltimore Maryland USA 2004: 337-340.
2. Susan Standring, Harold Ellis, Jeremiah C Healy, David Johnson, Andrew William. Grays' Anatomy. Testes and Epididymes 39th edition Elsevier Churchill Livingstone 2004; 1305-1310.
3. Fujisawa M, Yoshida S, Matsumoto O, Kojima K, Kamidono S. Deoxyribonucleic acid polymerase activity in the testes of infertile men with varicocele. Fertility Sterility 1988a; 50: 795-800.
4. Fujisawa M, Yoshida S, Matsumoto O, Kojima K, Kamidono S. Decrease of topoisomerase I in testes of infertile men with varicocele. Arch. Androl. 1988b; 21: 45-50.
5. Harrison RM, Lewis RW, Roberts JA. Testicular Blood flow and fluid dynamics in monkeys with surgically induced varicoceles. Journal of Andrology 1983; 256-260.

Inguinal Hernia and Spermatic Tract System

6. Saypol DC, Howards SS, Turner TT, Miller ED, Jr. Influence of surgically induced Varicocele on testicular blood flow, temperature and histology in adult rats and dogs. *J. Clin. Invest.* 1981; 68: 39-45.
7. Sweeney TE, Rozum JS, Gore RW. Alteration of testicular micro vascular pressures during venous pressure elevation. *Am. J Physiol.* 1995; 269 (1 pt 2): H37.
8. Skoog SJ, Roberts KP, Goldstein M, and Pryor JL, The adolescent varicocele: What's new with an old problem in young patients? *Pediatrics* 1997; 100: 112-116.
9. Hadziselimovic F, Herzog B Leibundgut B, Jenny P, Buser M. Testicular and vascular changes in children and adults with varicocele. *J. Urol.* 1989; 142: 583-587.
10. Chakraborty J, Hikim AP, Jhunjunwala JS. Stagnation of blood in the micro-circulatory vessels in the testis of men with varicocele. *J. of Andrology* 1985; 6: 117-120.
11. Schlatt S, Meinhardt A Neischlag E. Paracrine regulation of cellular interactions in testis: factors in search of function. *Exp. J. Endocrinol.* 1997; 137: 107- 117.
12. Schlatt S, Meinhardt A Weinbauer GF, Behre HM, Nieschlag E. Endocrine control of testicular somatic and premeiotic germ cell development in the immature testis of the primate *Macaca mullata*. *Eu. J Endocrinol.* 1995; 133: 235-247.
13. Mather JP, Moore A Li RH. Activins inhibins and follistatins: further thoughts on a growing family of regulators. *Proc Soc. Exp Biol & Med.* 1997; 215: 209-222.
14. Su LM, Goldstein M, Schlegel PN. The effect of varicocelectomy on serum testosterone levels in infertile men with varicoceles. *J. Urol.* 1995; 154: 1752-1755.
15. Hampl R, Lachman M, Novak Z, Sulcova J, Starka L. Serum levels of steroid hormones in men with varicocele and oligospermia as compared to normozoospermic men. *Exp. Clin Endocrinol.* 1992; 100: 117-119.
16. McFadden MR, Mehan DJ. (1978) Testicular biopsies in 101 cases of varicose. *J Urol.* 1978; 119: 372-374.
17. Hadziselimovic F, Leibundgut B, Da Ragna D, Buser MW. The value of testicular biopsy in patients with varicocele. *. Journal of Urology* 1986; 135: 707-710.
18. Sirvent JJ, Bernet, NavarroMA, Rodriguez Tolra J, Guspi R, Bosch R. Ledig cell in idiopathic varicocele. *Eu. Urol.* 1990; 17: 257-261.

Correspondence to:

M Tariq Zaidi
Department of Anatomy
Jawaharlal Nehru Medical College
Aligarh Muslim University
Aligarh 202002
India

